

# ***PCI in Patients with Transplant Coronary Artery Disease***

Michael S. Lee, MD, FACC, FSCAI

Assistant Professor

UCLA School of Medicine



# Faculty Disclosure

- Honararia for Boston Scientific, BMS, Daiichi Sankyo, Novartis, and Merck

# Cardiac Transplantation

- Orthotopic heart transplantation (OHT) is a well-established therapeutic option for patients with severe congestive heart failure.
- Approximately 2000 OHT are performed every year.<sup>1</sup>
- Within the first year post-op, *rejection* and *infection* are the most common causes of death.

1. Schroeder JS. Disorders of the Cardiovascular System. Harrison's Principle of Internal Medicine. 2001



**STATE-OF-THE-ART PAPER**

---

## Transplant Coronary Artery Disease

Raymond J. Zimmer, MD, Michael S. Lee, MD

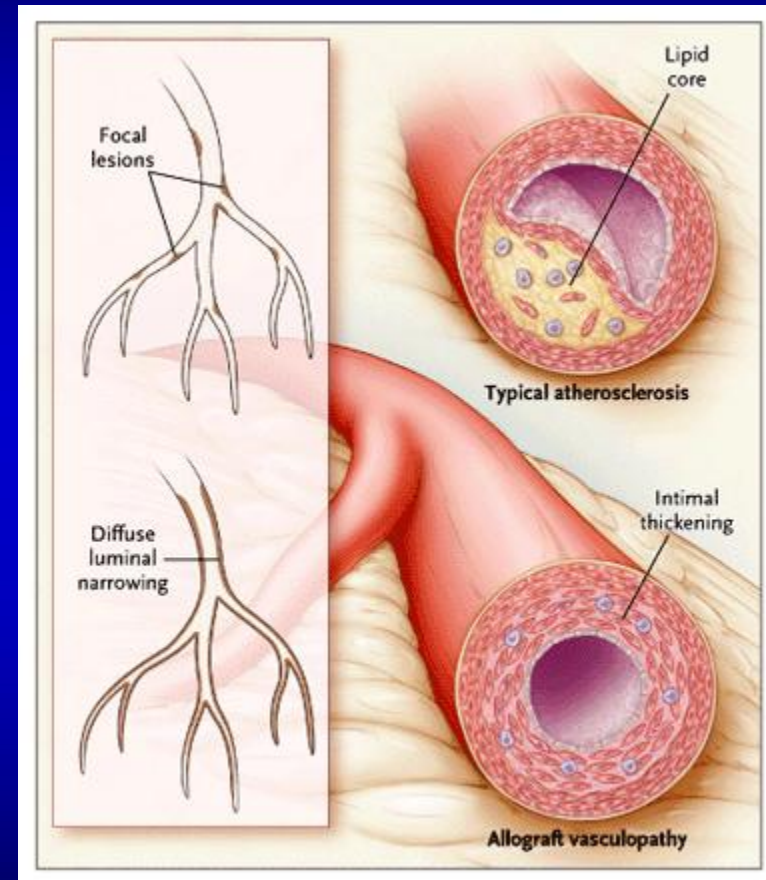
*Los Angeles, California*

---

Transplant coronary artery disease (TCAD) remains the most significant cause of morbidity and mortality after orthotopic heart transplantation. Transplant coronary artery disease is largely an immunologic phenomenon, driven by an inflammatory milieu consisting of multiple cell types that contribute to fibromuscular and smooth muscle cell proliferation with subsequent coronary obstruction. Multiple clinical factors contribute to the development of TCAD. Coronary angiography is the gold standard for the diagnosis of TCAD. Current treatments for TCAD include pharmacotherapy, percutaneous coronary intervention, and repeat transplantation, although other novel therapies are emerging. Although percutaneous coronary intervention has generally demonstrated high procedural success rates, it has been plagued by a high incidence of in-stent restenosis. Drug-eluting stents reduce in-stent restenosis compared with bare metal stents. Repeat transplantation is the only definitive treatment. Prospective randomized trials comparing different pharmacotherapies as well as revascularization strategies are needed to identify the optimal therapy for patients who develop TCAD. (J Am Coll Cardiol Intv 2010; 3:367-77) © 2010 by the American College of Cardiology Foundation

# Transplant Coronary Artery Disease

- **Transplant Coronary Artery Disease (TCAD)** is a rapidly progressive form of *diffuse arterial narrowing*
- TCAD is characterized by
  1. Endothelial dysfunction
  2. Luminal narrowing
  3. Intimal hyperplasia



# Transplant Coronary Artery Disease

- TCAD is the major cause of late death in transplant patients and is the primary cause of allograft loss.<sup>1</sup>
- At 5 years after OHT, 50% of patients have angiographic evidence of TCAD.<sup>2</sup>
- When the diagnosis of TCAD is made, long-term prognosis is poor, and the 5-year life expectancy of the allograft is approximately 17%.<sup>3</sup>

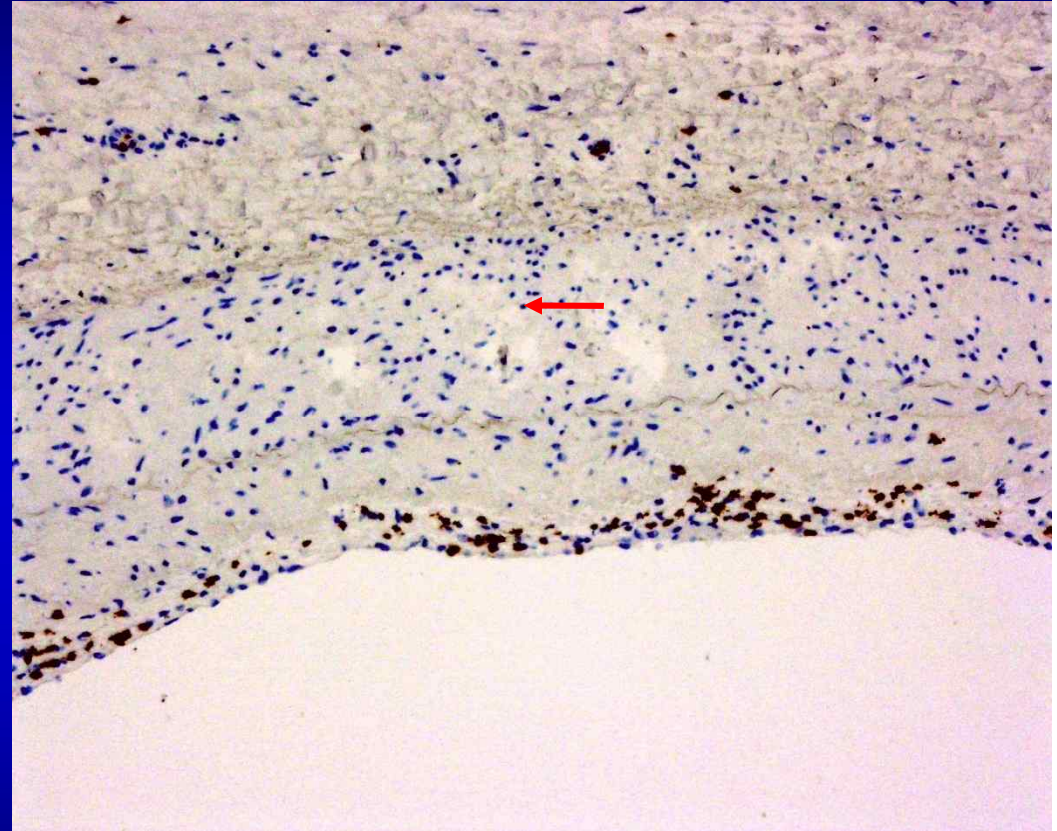
1. Taylor DO, et al. J Heart Lung Transplant 2004.

2. Miller LW, et al. J Am Coll Cardiol 1993.

3. Gao SZ, et al. J Heart Lung Transplant 1994.

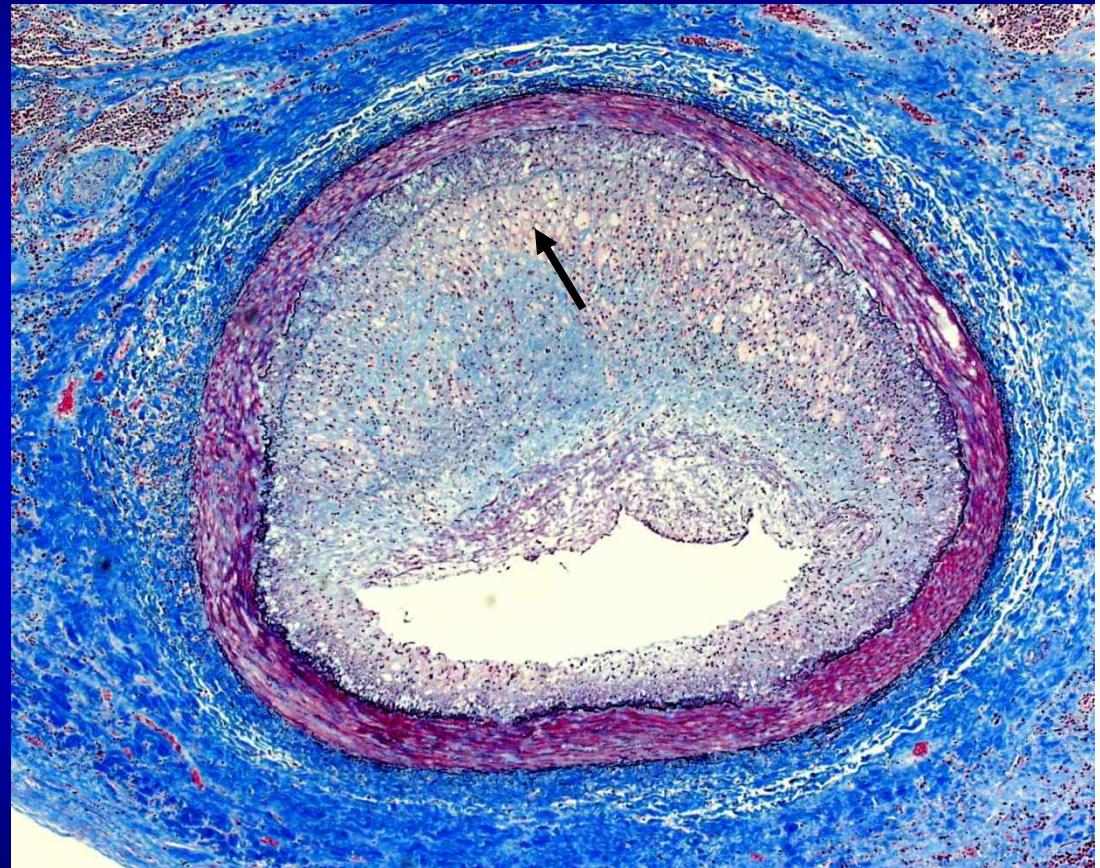
# Histology of Transplant Coronary Artery Disease

- Subendothelial accumulation of **T lymphocytes** (arrow) characteristic of endothelitis, which is a manifestation of chronic rejection



# Histology of Transplant Coronary Artery Disease

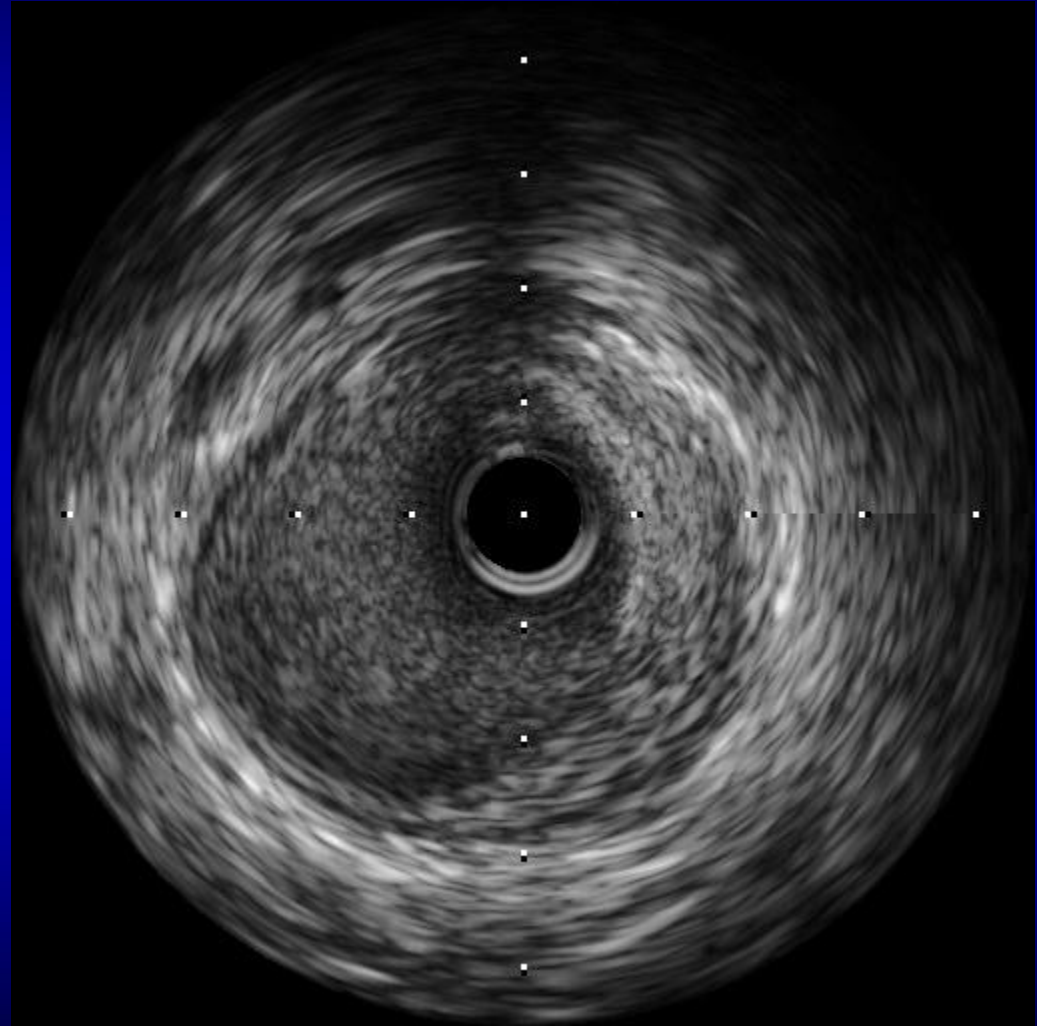
- Progressive arterial occlusion with *lipid-laden foam cell macrophages*
- This intense inflammatory response is believed to play a key role in TCAD and may be responsible for the increased risk of restenosis after PCI





# Vascular Remodeling

**Positive remodeling is a compensatory mechanism in patients with TCAD that prevents luminal narrowing despite intimal hyperplasia.**



# Medical Therapy for Transplant Coronary Artery Disease

- **Statins may decrease the incidence of TCAD, graft rejection, and increase long-term survival.<sup>1</sup>**
- **However, there currently is no medical therapy to reverse CAV.**

1. Kobashigawa JA, et al. N Engl J Med 1995.

# PCI for the Treatment of Transplant Coronary Artery Disease

- Used as a palliative treatment option for TCAD
- When compared with native coronary artery lesions it is associated with
  - Higher procedural complications
  - Long-term morbidity and mortality
  - Higher restenosis rates

# CABG for the Treatment of Transplant Coronary Artery Disease

- **Distal arteriopathy** (diffuse, predominantly distal vessel disease) is prevalent in OHT patients and therefore makes CABG technically difficult and a poor treatment option
- *Repeat sternotomy* and the associated mediastinal scarring and risk of infection in these immunocompromised patients may increase the risk of complications.
- The *perioperative mortality rate* is high (40%-80%), and the long-term patency rates of bypass grafts are unknown.<sup>1</sup>
- CABG in patients with left main disease is also associated with a higher incidence of stroke, pneumonia, and a longer length of stay compared with PCI.<sup>2</sup>
- In addition, 7% of patients required repeat operation for significant bleeding.

1. Halle AA, et al. J Am Coll Cardiol 1995.

2. Taylor HA, et al. Circulation 1989.

# Repeat OHT for the Treatment of Transplant Coronary Artery Disease

- Repeat OHT is associated with high perioperative mortality and poor long-term survival.<sup>1</sup>
- 1-year mortality rate of 25%.<sup>2</sup>
- 50% develop recurrent TCAD in the second graft.<sup>3</sup>
- Shortage of organs.
- Ethical dilemma

1. Gao SZ, et al. Am J Cardiol 1988

2. Parry A, et al. Eur J Cardiothorac Surg 1996

3. Musci M, et al. Thorac Cardiovasc Surg 1998



## Comparison of Percutaneous Coronary Intervention With Bare-Metal and Drug-Eluting Stents for Cardiac Allograft Vasculopathy

Michael S. Lee, MD, Jon Kobashigawa, MD, Jonathan Tobis, MD

*Los Angeles, California*

**Objectives** We sought to compare percutaneous coronary intervention (PCI) with bare-metal stents (BMS) and drug-eluting stents (DES) for cardiac allograft vasculopathy (CAV).

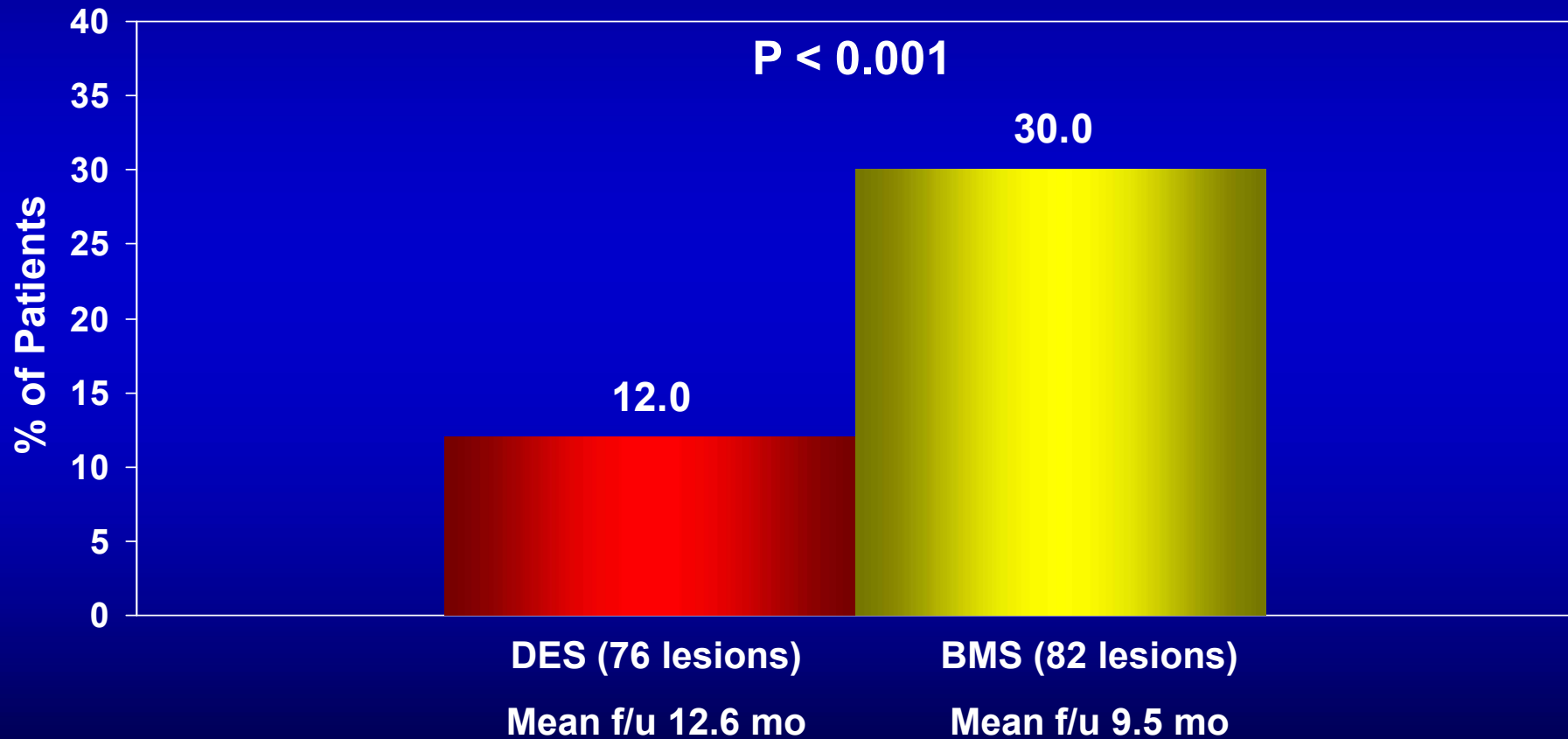
**Background** Cardiac allograft vasculopathy is a rapidly progressive form of atherosclerosis and is one of the main limitations to long-term survival after orthotopic heart transplantation. Percutaneous coronary intervention has been used as a palliative treatment option for CAV but is associated with worse clinical outcomes and greater rate of restenosis compared with PCI of native coronary arteries.

**Methods** Between 1995 and 2007, data on 82 consecutive heart transplant patients who underwent PCI with BMS and DES at the University of California at Los Angeles Medical Center were retrospectively analyzed.

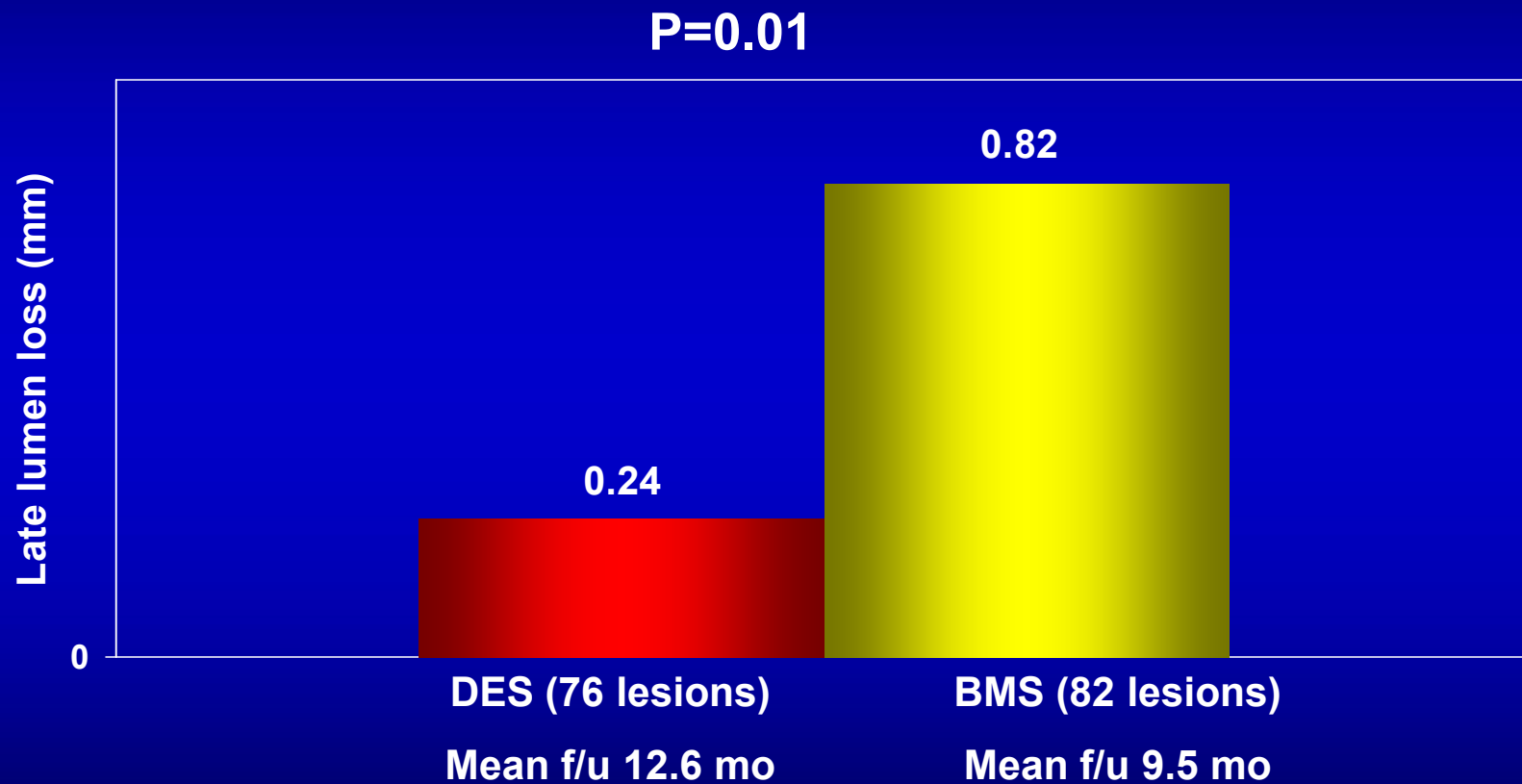
**Results** A total of 82 lesions were treated with 98 BMS and 76 lesions were treated with 80 DES. Follow-up angiography was performed on 57 of 82 lesions (70%) treated with BMS and 58 of 76 (76%) treated with DES ( $p = 0.7$ ) at a mean follow-up of  $9.5 \pm 5.5$  months for BMS and  $12.6 \pm 8.2$  months for DES ( $p = 0.02$ ). Compared with BMS, DES was associated with a lower binary restenosis rate (12% vs. 30%,  $p = 0.02$ ), lower percent diameter stenosis ( $24 \pm 20$  vs.  $34 \pm 36$ ,  $p = 0.06$ ), and less late lumen loss ( $0.24 \pm 0.75$  mm vs.  $0.82 \pm 1.03$  mm,  $p = 0.01$ ). No angiographic stent thrombosis was observed with DES.

**Conclusions** When compared with BMS, PCI with DES was safe and reduced the rate of angiographic restenosis in patients with CAV. A randomized clinical trial comparing BMS versus DES with longer follow-up is needed to identify the optimal long-term revascularization strategy in patients with CAV. (J Am Coll Cardiol Intv 2008;1:710-5) © 2008 by the American College of Cardiology Foundation

# Binary Restenosis at Follow-Up



# Late Lumen Loss at Follow-Up





# Stent Thrombosis in Cardiac Transplant Patients

Bare metal stents

N=98

2 lesions were totally occluded on follow-up angiography

Cypher™

N=58

No angiographic stent thrombosis

TAXUS

N=22



## CLINICAL RESEARCH

# Sirolimus- Versus Paclitaxel-Eluting Stents for the Treatment of Cardiac Allograft Vasculopathy

Michael S. Lee, MD,\* Giuseppe Tarantini, MD,† Jola Xhaxho, MD,† Tae Yang, MD,\* Ashkan Ehdaie, MD,\* Ravi Bhatia, MD,\* Enrico Favaretto, MD,† Jonathan Tobis, MD\*

*Los Angeles, California; and Padua, Italy*

**Objectives** The aim of this study was to compare outcomes after percutaneous coronary intervention (PCI) with sirolimus-eluting stents (SES) and paclitaxel-eluting stents (PES) in the treatment of cardiac allograft vasculopathy (CAV).

**Background** PCI in patients with CAV is associated with increased rates of restenosis compared with PCI in patients without CAV. There are no dedicated studies on the influence of different drug-eluting stents (DES) on the outcomes of patients with CAV.

**Methods** This is a retrospective observational study of 108 consecutive patients with CAV who underwent PCI with SES and PES at UCLA Medical Center and University of Padova Medical Center between 2002 and 2008.

**Results** Baseline characteristics were similar among SES (n = 68) and PES (n = 40) patients with the exception of older patients, larger minimal lumen diameter, and smaller diameter stenosis in the SES-treated patients. Angiographic follow-up at 1 year was high in the SES and PES groups (74% vs. 76%, p = 0.8). The SES and PES groups had similar binary restenosis rates (10% vs. 9%, p = 0.7), percent diameter stenosis ( $24 \pm 24\%$  vs.  $24 \pm 18\%$ , p = 0.94), and late lumen loss ( $0.67 \pm 1.03$  mm vs.  $0.68 \pm 1.11$  mm, p > 0.9). One-year clinical outcomes were not significantly different among CAV patients treated with either SES or PES (major adverse cardiac events: 10% vs. 15%, p = 0.5; death: 3% vs. 5%, p = 0.4; myocardial infarction: 3% vs. 5%, p = 0.4; target vessel revascularization: 4% vs. 8%, p = 0.3).

**Conclusions** In patients who underwent PCI for CAV, both SES and PES were safe and effective with no significant differences in clinical and angiographic outcomes. Randomized clinical trials comparing different DES with longer follow-up are necessary to identify the optimal treatment strategy for patients with CAV. (J Am Coll Cardiol Intv 2010;3:378–82) © 2010 by the American College of Cardiology Foundation

**Table 3. 1-Year Angiographic Outcomes**

	<b>SES (n = 68)</b>	<b>PES (n = 40)</b>	<b>p Value</b>
Follow-up angiography	50 (74)	30 (76)	0.8
Binary restenosis	7 (10)	4 (9)	0.7
Percent diameter stenosis	24 ± 24	24 ± 18	0.9
Late lumen loss (mm)	0.67 ± 1.03	0.68 ± 1.11	>0.9
MLD (mm)	2.25 ± 0.78	2.31 ± 0.70	0.8

**Table 4. 1-Year Clinical Outcomes**

	<b>SES (n = 68)</b>	<b>PES (n = 40)</b>	<b>p Value</b>
Major adverse cardiac events	7 (10)	6 (15)	0.5
Cardiac death	2 (3)	2 (5)	0.4
Myocardial infarction	2 (3)	2 (5)	0.4
Target vessel revascularization	3 (4)	3 (8)	0.3
Target lesion revascularization	2 (3)	1 (3)	0.9
Stent thrombosis	1 (1.5)	2 (5)	0.3
Repeat transplantation	0 (0)	0 (0)	>0.9

# Treatment Options for Cardiac Transplant Patients With Left Main Disease

- Medical therapy is probably not an option, as the only clinical manifestation of left main disease may be sudden death
- Medical therapy for left main disease in non-transplant patients has been associated with a 3-year mortality rate of approximately 50%.<sup>1</sup>

1. Taylor HA, et al. Circulation 1989.



## Drug-Eluting Stenting of Unprotected Left Main Coronary Artery Stenosis in Patients With Orthotopic Heart Transplantation: Initial Clinical Experience

Michael S. Lee,\* MD, Kook-Jin Chun, MD, and Jonathan M. Tobis, MD

- 8 out of 82 transplant patients who underwent PCI had left main disease
- 5 of the 8 transplant patients underwent PCI with DES

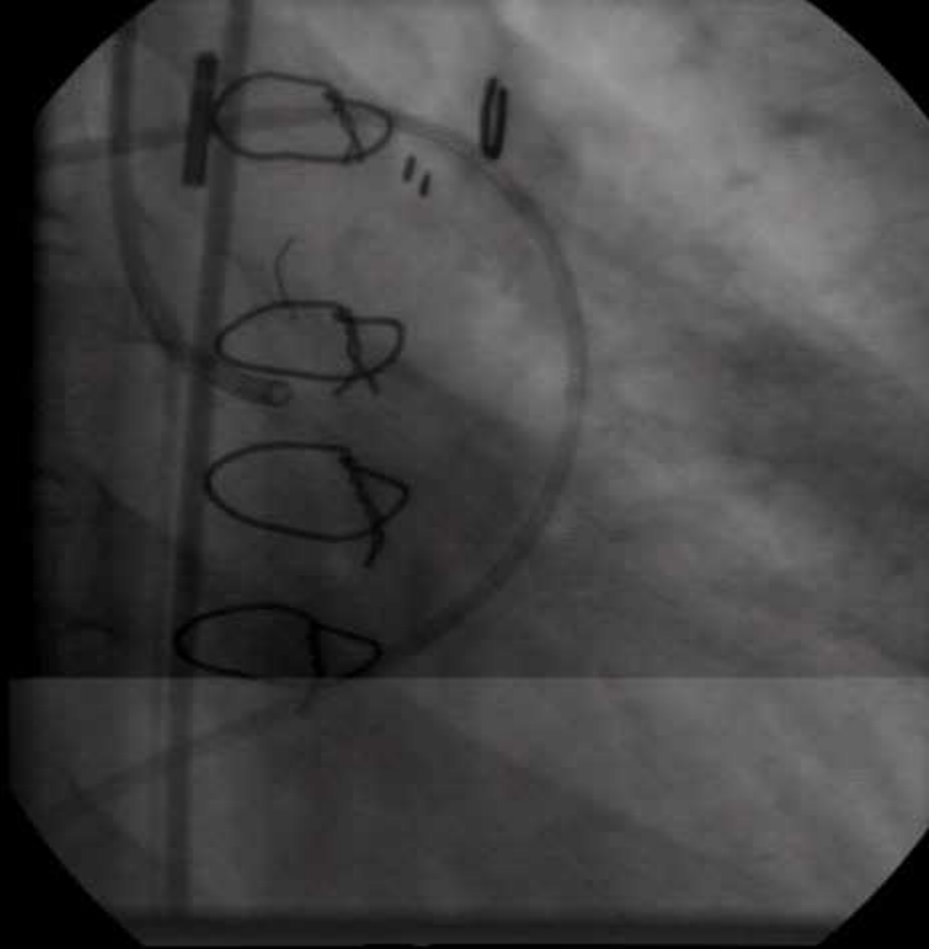
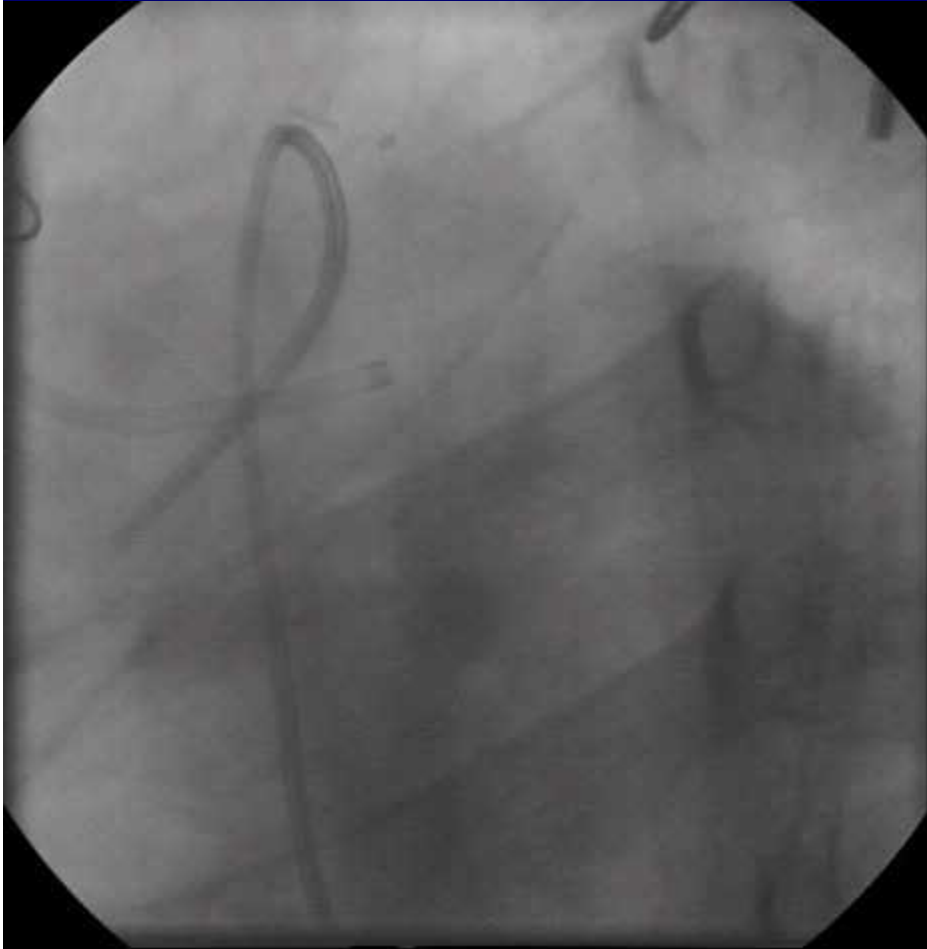
patients is unknown. **Methods:** From April 2005 to December 2006, five OHT patients with ULMCA disease underwent PCI with DES at the University of California, Los Angeles, Medical Center. **Results:** Technical success was achieved in all five patients. At a median follow-up of 518 days (range 124–990 days), all five patients were alive and free from death, myocardial infarction, and target vessel revascularization. No binary restenosis was present in four patients who underwent surveillance angiography. One patient underwent repeat OHT for progressive left ventricular dysfunction. **Conclusions:** In OHT patients, ULMCA PCI with DES is feasible with an excellent technical success rate and is a reasonably palliative treatment option for this difficult patient population. © 2008

Wiley-Liss, Inc.

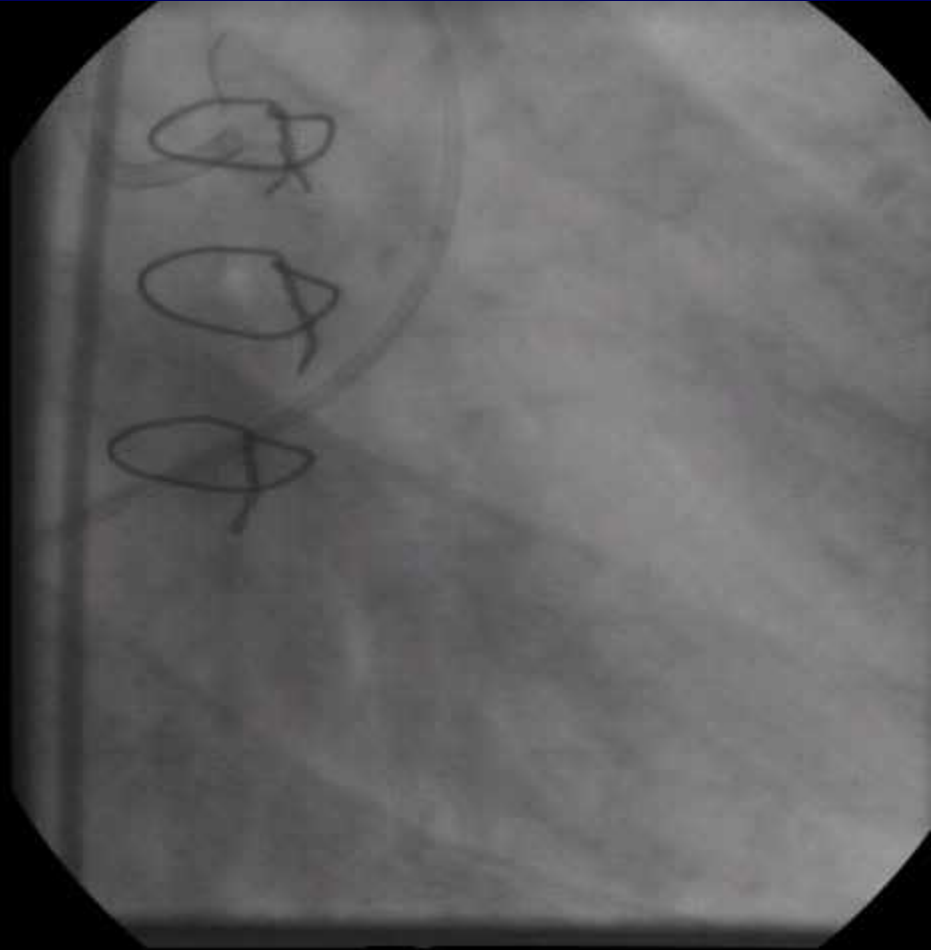
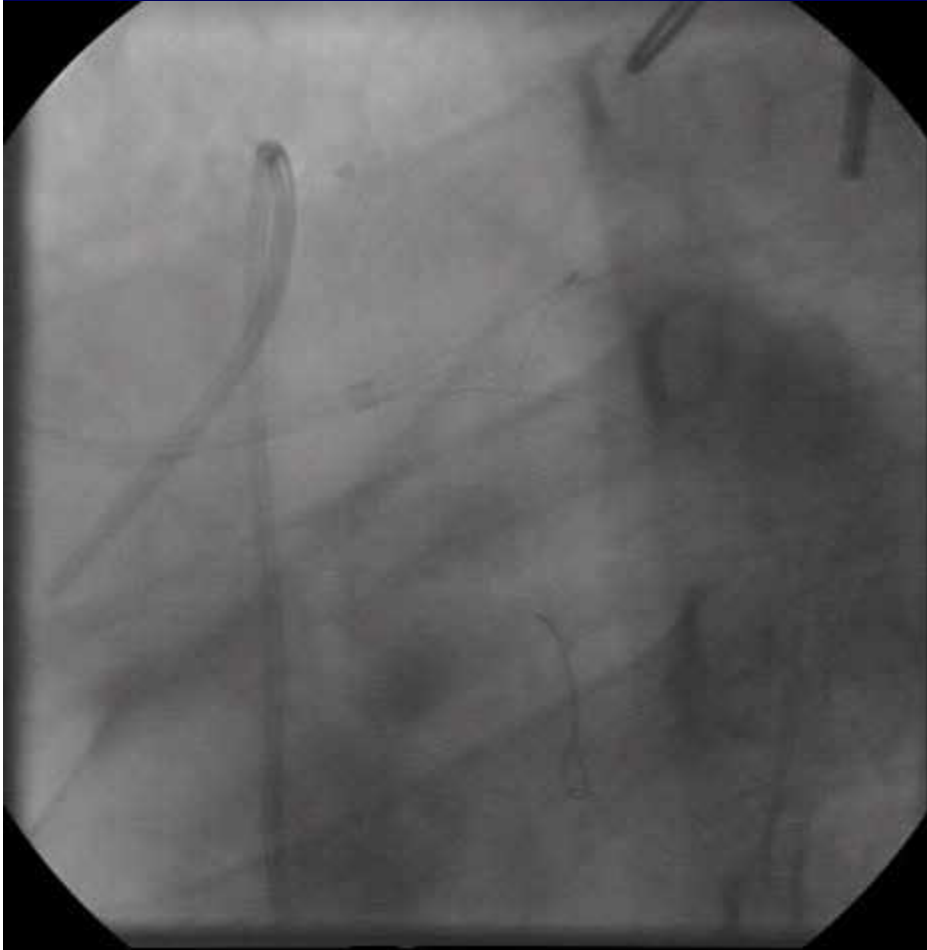


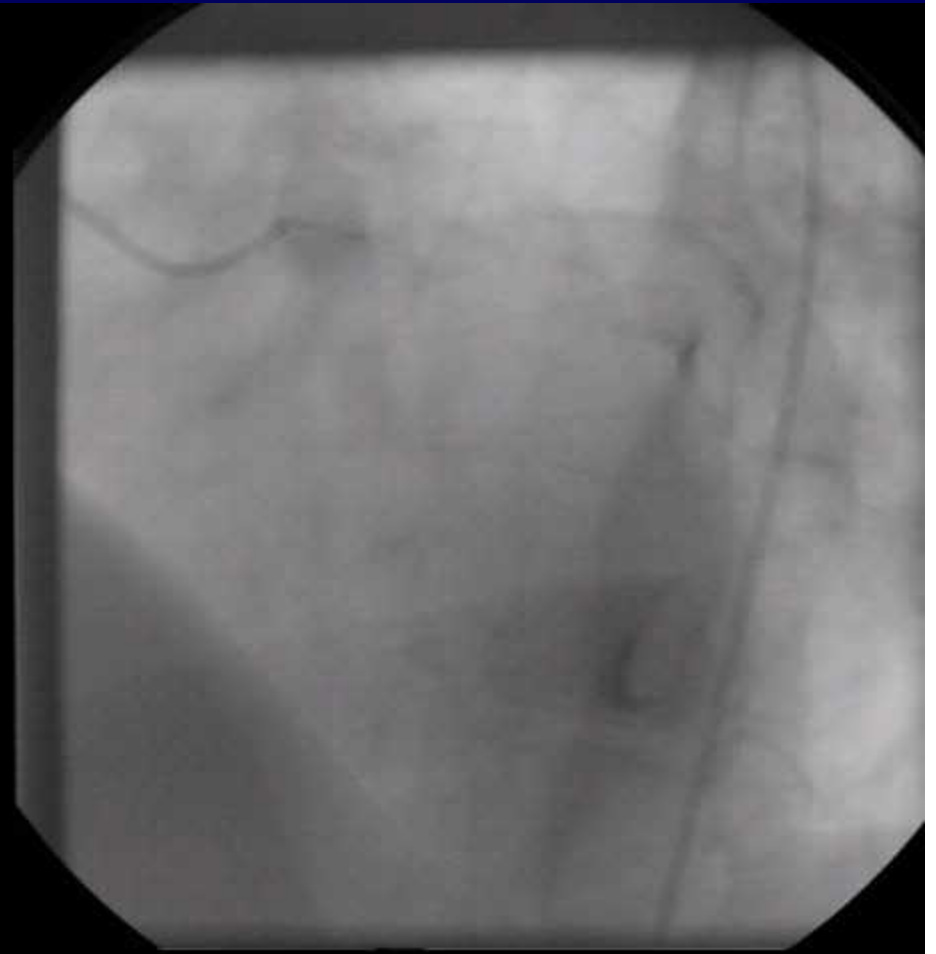
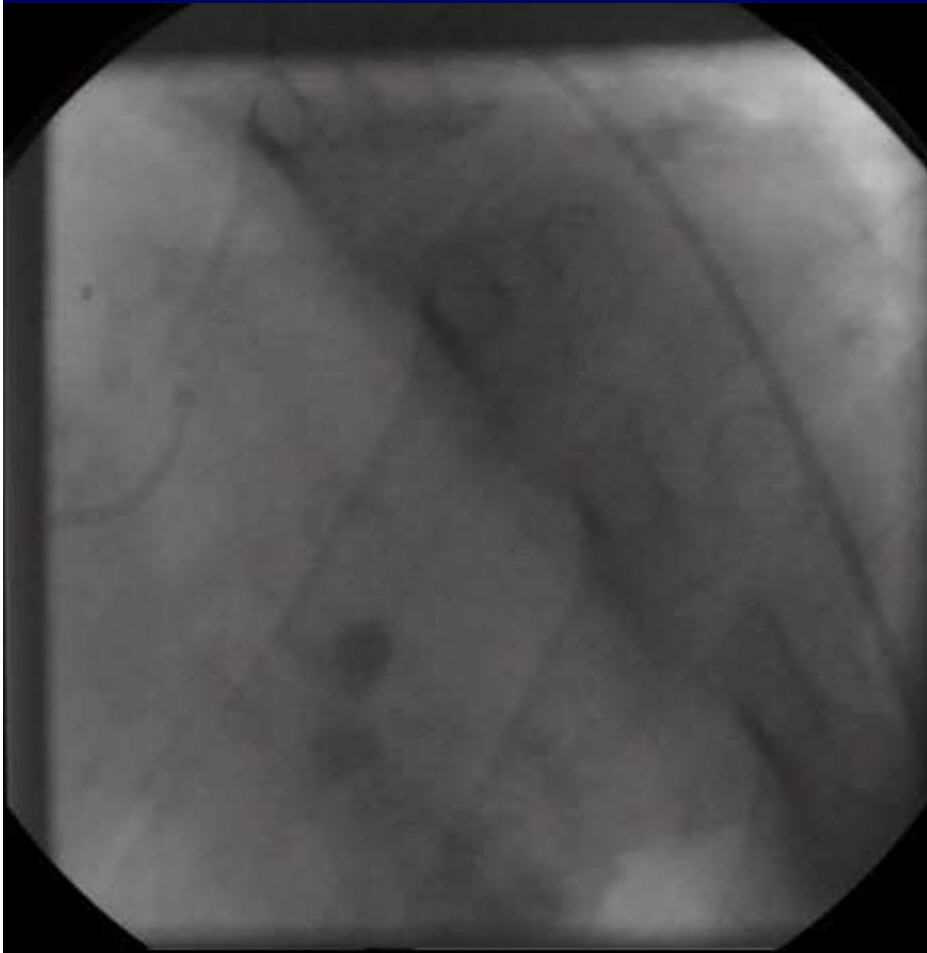
# PCI with DES for Unprotected Left Main Disease in Cardiac Transplant Patients

- 23 year-old male with a past medical history of cardiac transplantation 5 years ago and LV dysfunction (EF = 40%) underwent annual surveillance angiography










# Left Main PCI in Cardiac Transplant Patients



# Conclusions

- **In transplant patients, PCI is safe, technically feasible, with excellent technical results and may serve as a bridge to repeat OHT.**
- **Although improvements in DES and pharmacotherapy may decrease the risk of restenosis and stent thrombosis, randomized trials with long-term f/u are needed to determine the ideal treatment for this difficult patient population.**
- **However, because ULMCA disease in transplant patients is uncommon, such a clinical trial may not be practical.**

*Thank you!*

